

DATE PRESENTING CLINICAL SIGNS

1/5/22

History: Grade 4/6 murmur. Radiographic cardiomegaly. Receiving pimobendane.

ECHOCARDIOGRAPHIC FINDINGS

PERFORMED BY:

2D, M-mode, and Doppler study.

Potomac Mobile
Veterinary
Ultrasound

Left atrial size is normal. The mitral valve leaflets are mildly thickened, and there is Doppler evidence of mitral regurgitation present. Left ventricular dimensions are normal. Left ventricular systolic function is mildly hyperdynamic. The aorta and aortic valve appear normal, though mild aortic insufficiency is present. Right atrial and right ventricular dimensions are normal. The tricuspid valve is normal. The pulmonary artery and pulmonic valve are normal. No shunting lesions are visualized. No pericardial effusion or cardiac masses are seen.

INTERPRETED BY

Keith Blass, DVM,
MS, DACVIM
(Cardiology)

LA - 28.4 mm
LVIdD - 27.0 mm
LVIDs - 15.1 mm
FS - 44%

PATIENT

LVOT - 1.32 m/s
RVOT - 0.61 m/s

Bubbles Khan

ASSESSMENT/RECOMMENDATIONS

Degenerative mitral valve disease

SPECIES

Canine

This examination demonstrates regurgitation of blood across Bubbles' mitral valve resulting from degenerative valve disease. The hemodynamic effects of the regurgitation appear to be mild, as Bubbles does not have secondary dilation of either of her left heart chambers, and her left ventricular systolic function is well-preserved. As such, Bubbles' mitral valve disease appears to be well-compensated, and her current risk for the development of clinical signs secondary to it, such as coughing, exercise intolerance, syncope, and labored breathing, appears to be relatively low.

BREED

Shih Tzu

No change in therapy is recommended based on this exam.

SEX

A recheck echocardiogram is recommended in 9 months. Thoracic radiographs are recommended if Bubbles experiences respiratory clinical signs.

FS

AGE

11 y

WEIGHT

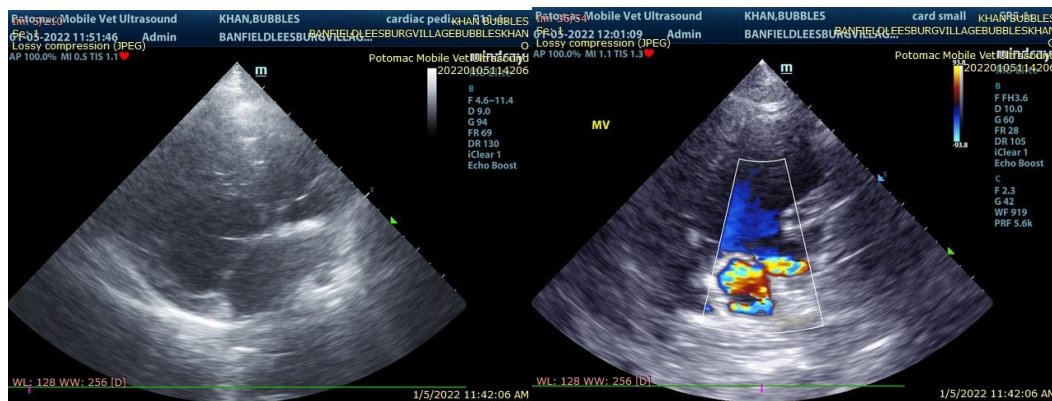
20.2 lb

HOSPITAL NAME

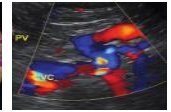
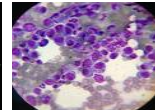
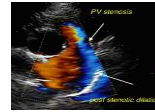
Banfiled Leesburgh
Village

REFERRING VET

Dr. Jarrett



The information and recommendations provided are based on the images presented by the referring veterinarian. No evaluation can be communicated regarding pathology that was not visible in the image/video clips provided.



DATE

1/5/22

Thank you for this referral. If the clinical or image interpretation does not parallel your findings or if I can be of any further assistance please contact me.

PERFORMED BY:

Keith Blass, DVM, MS, DACVIM (Cardiology)

KeithBlass@gmail.com

631-804-5754

Potomac Mobile
Veterinary
Ultrasound

INTERPRETED BY

Keith Blass, DVM,
MS, DACVIM
(Cardiology)

PATIENT

Bubbles Khan

SPECIES

Canine

BREED

Shih Tzu

SEX

FS

AGE

11 y

WEIGHT

20.2 lb

HOSPITAL NAME

Banfiled Leesburgh
Village

REFERRING VET

Dr. Jarrett